

LAPAROSCOPIC LIVE DONOR NEPHRECTOMY

LLOYD E. RATNER,^{1,2} LARS J. CISECK,³ ROBERT G. MOORE,³ FRANCISCO G. CIGARROA,¹
HOWARD S. KAUFMAN,¹ AND LOUIS R. KAVOUSSI³

Departments of Surgery and Urology, Johns Hopkins University School of Medicine and Johns Hopkins Bayview Medical Center, Baltimore, Maryland

A laparoscopic live-donor nephrectomy was performed on a 40-year-old man. The kidney was removed intact via a 9-cm infraumbilical midline incision. Warm ischemia was limited to less than 5 min. Immediately upon revascularization, the allograft produced urine. By the second postoperative day, the recipient's serum creatinine had decreased to 0.7 mg/dl. The donor's postoperative course was uneventful. He experienced minimal discomfort and was discharged home on the first postoperative day.

We conclude that laparoscopic donor nephrectomy is feasible. It can be performed without apparent deleterious effects to either the donor or the recipient. The limited discomfort and rapid convalescence enjoyed by our patient indicate that this technique may prove to be advantageous.

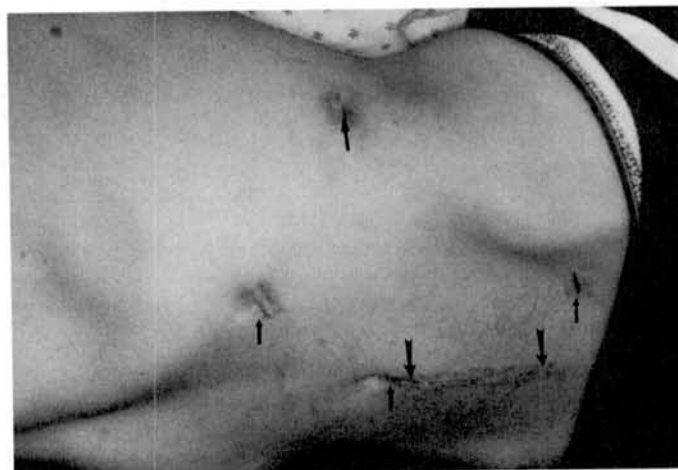


FIGURE 1. The small arrows identify the location of the instrument ports. The large arrows indicate the extent of the 9-cm lower midline incision used for extraction of the kidney.

Recent improvements in video technology and surgical instrumentation have resulted in the application of minimally invasive techniques to a myriad of surgical procedures. In many instances, laparoscopic procedures have proven more advantageous when compared with the standard open approach. Laparoscopic nephrectomy was first successfully performed clinically in 1990 by Clayman and associates (1). It is now offered routinely to patients in several institutions for both benign and malignant diseases. It has proven efficacious with minimal morbidity, decreased postoperative pain, shorter convalescent time, and decreased length of hospital stay (2, 3). Gill et al. (4) have demonstrated the feasibility of laparoscopic donor nephrectomy in a porcine model. We report the first case in which a live-donor laparoscopic nephrectomy was performed. The clinical course, operative technique, and potential advantages are discussed.

J.S. was a 41-year-old woman (HLA: A1,2 B8,39 DR13,17) with end-stage renal disease secondary to glomerulonephritis. Her brother, J.G., a 40-year-old man (HLA: A2,3 B18,39 DR1,17), volunteered to donate his kidney. Laparoscopic donor nephrectomy was discussed at length with both the donor and recipient and informed consent for the procedure was obtained. The surgery was performed on February 8, 1995.

The donor was placed in a modified left lateral decubitus position. Pneumoperitoneum was established via a Veress needle. Four 12-mm ports were placed in the abdomen (at the umbilicus, 2 cm medial to the left anterior superior iliac spine, 2 cm anterior to the left eleventh rib, and in the midaxillary line at the level of the umbilicus; Fig. 1). The videoendoscope was inserted via the umbilical port. After the descending colon was mobilized medially by incising the lateral peritoneal reflection, Gerota's fascia was identified and

entered. The lateral aspect of the kidney was freed. Mobilization of the lower pole enabled identification of the ureter. The ureter and a generous mesoureter were dissected from surrounding structures to the level of the iliac bifurcation. The ureter was divided approximately 12 cm distal to the lower pole of the kidney, after the distal limb was occluded with a 9-mm endostapler. By utilizing sharp dissection, the upper pole was isolated from adjacent structures. The kidney was then reflected medially and posterior attachments were divided. At this point, the kidney was free from all attachments except the renal vessels.

The renal vein was identified in the hilum and dissected medially. This allowed for identification of the gonadal and adrenal veins, which were clipped and divided. With the vein retracted anteriorly, the renal artery was recognized and dissected free to its origin at the aorta (Fig. 2). In preparation for removal of the kidney, the umbilical trocar incision was extended inferiorly to create a 9-cm midline incision. This was carried down to, but not through, the peritoneum. The renal artery was occluded proximally with two 9-mm vascular clips and divided. The renal vein was transected anterior to the aorta utilizing an endovascular-GIA stapler. The peritoneum was then incised and the kidney was removed manually from the peritoneal cavity. Direct camera vision from the perspective of the iliac trocar facilitated localization of the kidney for extraction. The kidney was subsequently flushed with an iced modified Euro-Collins solution. Total warm ischemic time was limited to under 5 min. Operative time for the donor nephrectomy was 3.5 hr. No intraoperative complications occurred. Blood loss was minimal.

Oral intake was tolerated the evening of surgery and the donor was discharged home on the first postoperative day. He experienced minimal postoperative pain. Total parenteral

¹ Department of Surgery.

² Address correspondence to: Lloyd E. Ratner, Department of Surgery, Johns Hopkins Bayview Medical Center, B2N Room 203, 4940 Eastern Avenue, Baltimore, MD 21224.

³ Department of Urology.

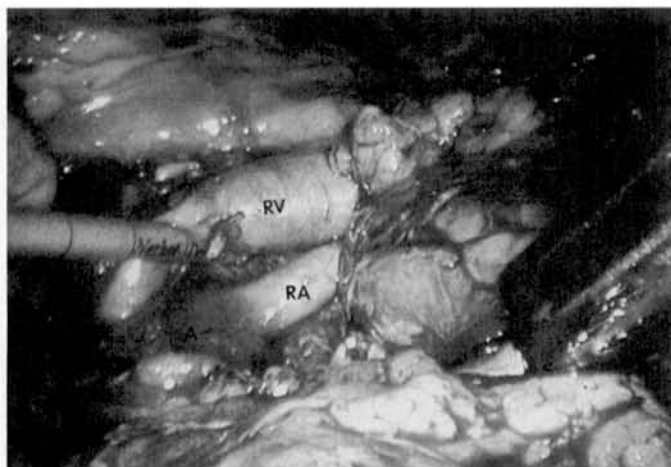


FIGURE 2. Laparoscopic video magnification aids in the dissection of the renal vessels. The renal vein (RV) is elevated by the suction/irrigator, thus exposing the renal artery (RA). The origin of the renal artery at the aorta (A) is clearly visualized.

analgesic requirements consisted of 20 mg of morphine sulfate in the recovery room and 100 mg of meperidine on the morning of the first postoperative day. Within 7 days of surgery, the donor had no further pain. He returned to work as a welder 2 weeks after surgery.

The recipient operation was also uneventful. Adequate lengths of renal artery, vein, and ureter were provided (Fig. 3). Urine production commenced immediately upon revascularization. By the second postoperative day, the recipient's serum creatinine level had decreased to 0.7 mg/dl. She was discharged home on the ninth postoperative day with a creatinine level of 0.6 mg/dl on triple immunosuppression consisting of azathioprine, prednisone, and FK506.

This case demonstrates that laparoscopic live-donor nephrectomy can be performed without detriment to either the donor or the recipient. By placing the incision in a low midline position, we believe we markedly decreased the morbidity usually associated with the traditional flank incision. Laparoscopic visualization affords excellent exposure to the kidney and the hilar structures. Video magnification facili-

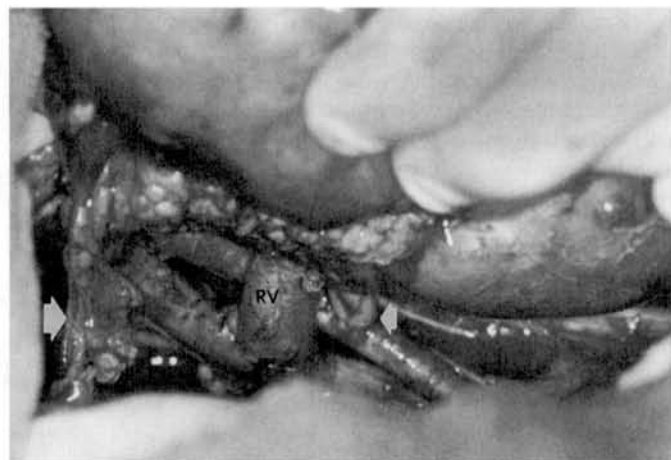

FIGURE 3. Adequate lengths of allograft ureter (large arrow), renal vein (RV), and renal artery (small arrow) were obtained. This is exhibited here with the kidney in situ after transplantation.

tates dissection of the renal vessels. The laparoscopically retrieved kidney had sufficient length of renal vein, renal artery, and ureter for standard allograft implantation. Studies done in a porcine laparoscopic donor nephrectomy model demonstrated that the lengths of the renal vessels and the ureter were similar for those kidneys harvested laparoscopically and those removed by the conventional approach (4). Warm ischemic time in the porcine model averaged 9.8 ± 7.2 min (4). However, we were able to limit the warm ischemia to under 5 min. Although this is acceptable, we are confident that, with increased experience, warm ischemic time can be further decreased. Similarly, as has been seen with laparoscopic cholecystectomy, total operative time should approach that expected for an open procedure.

The laparoscopic approach to live-donor nephrectomy that we performed was transperitoneal. The open anterior transperitoneal procedure is an accepted method for performing live-donor nephrectomies (5, 6) and results in minimal morbidity comparable to that of the extraperitoneal flank approach (7). The small lower midline incision that we used for extraction of the kidney was well tolerated. However, Yang et al. (8) have described a minimally invasive extraperitoneal open flank approach utilizing endoscopic visualization and purpose-built retractors, which may be an acceptable alternative.

This case has demonstrated not only that the laparoscopic approach to live-donor nephrectomy is technically feasible, but that it may provide significant advantages to the patient. In a retrospective review of open live-donor nephrectomies, Clayman et al. (9) have reported that the average dose of parenteral analgesia was 66 mg of morphine sulfate, the mean length of hospital stay was 6.4 days, and the average delay until resumption of full activity was 80 days. In other series of live-donor nephrectomies, lengths of stay ranging from 6 to 10 days have been reported (7, 10, 11). We retrospectively reviewed the previous 21 consecutive live-donor nephrectomies performed at our institution from January 1991 to January 1994 and found the mean length of hospitalization to be 5.6 ± 1.8 days. The 1-day hospital stay required by our patient compares favorably with our open-donor nephrectomy experience. Similarly, a low analgesic requirement was seen with this procedure. The expectation that postoperative pain and discomfort may be minimized by the laparoscopic approach is further supported by the series of 10 laparoscopic nephrectomies in which the average patient received only 19 mg of morphine sulfate and had returned to normal activity within 1.7 weeks (2).

Despite the extreme organ shortage, in 1993, live-donor transplantation accounted for only 24.8% of all renal transplants performed in the United States (12). The application of minimally invasive techniques to the donor nephrectomy operation, with its potential advantages of decreased pain and shorter convalescence, may make live donor renal transplantation more attractive. Conceivably, these advantages could increase the number of live-donor renal transplants performed and may help to alleviate the critical deficit of transplantable organs.

In the present climate of fiscal concern, the potential reduction in hospital stay offered by the laparoscopic approach may serve to lower donor costs. However, one caveat is that the use of relatively expensive disposable laparoscopic instruments and longer operating room times may partially

offset any savings. The potential benefit of more rapid return to normal activities and employment should not be minimized. One can predict that, as transplantation becomes the focus of more sophisticated outcomes research, shorter convalescence will tilt the economic balance in favor of the laparoscopic approach, even if savings in hospital charges are limited.

For live-donor nephrectomy, the reported mortality is 0.07% (13) and the incidence of major complications is 1–8% (7, 10, 13). To obtain similarly acceptable results with the laparoscopic operation, we are presently utilizing rather stringent selection criteria. Currently, thin individuals without a history of previous abdominal surgery are being considered as candidates. Additionally, normal renovascular and ureteral anatomy are required. However, it is anticipated that the laparoscopic approach will eventually be considered appropriate for most live donors as our comfort level increases with the technical aspects of the operation.

In the case reported here, the operation was performed by an experienced laparoscopic surgeon (L.R.K.) who routinely performs complex laparoscopic cases such as nephrectomies. We caution that a surgeon must possess a high degree of laparoscopic proficiency before attempting this procedure. Additionally, we recommend that there be a low threshold for open conversion if one encounters such difficulties as significant bleeding, or unexpected anatomic variants not diagnosed prospectively by angiography. Additional experience is required in a large number of patients before one can conclude that the laparoscopic approach should replace the standard open technique of live-donor nephrectomy. However, we believe that the potential benefits of the minimally invasive procedure justifies its continued careful application and assessment.

In summary, this case demonstrates that laparoscopic live-donor nephrectomy is technically feasible. The operation was performed safely. The integrity of the donated kidney was not compromised. Ureteral and vascular length were adequate and warm ischemic time was within acceptable limits. Additionally, the laparoscopic operation may offer advantages to the donor in terms of comfort and convenience. The potential decrease in hospitalization and convalescence observed with this operation may prove to be financially advantageous.

Based on the excellent results achieved with this case, we believe that further careful study of this procedure is warranted.

Acknowledgments. We thank Dr. Andrew Klein for reviewing the manuscript and Lisa Shirk and Gertrude Allen for their excellent secretarial assistance.

REFERENCES

1. Clayman RV, Kavoussi LR, Soper NJ, et al. Laparoscopic nephrectomy: initial case report. *J Urol* 1991; 146: 278.
2. Clayman RV, Kavoussi LR, Soper NJ, Albala DM, Figenshau RS, Chandhoke PS. Laparoscopic nephrectomy: review of the initial 10 cases. *J Endourol* 1992; 6(2): 127.
3. Kavoussi LR, Kerbl K, Capelouto CC, McDougal EM, Clayman RV. Laparoscopic nephrectomy for renal neoplasms. *Urology* 1993; 42: 603.
4. Gill IS, Carbone JM, Clayman RV, et al. Laparoscopic live-donor nephrectomy. *J Endourol* 1994; 8(2): 143.
5. Ruiz R, Novick AC, Braun WE, Montague DK, Stewart BH. Transperitoneal live donor nephrectomy. *J Urol* 1980; 123: 819.
6. Dunn JF, Nylander WA, Richie RE, Johnson HK, MacDonell RC, Sawyers JL. Living related kidney donors: a 14-year experience. *Ann Surg* 1986; 203(6): 637.
7. DeMarco T, Amin M, Harty JI. Living donor nephrectomy: factors influencing morbidity. *J Urol* 1982; 127: 1082.
8. Yang SC, Lee DH, Rha KH, Park K. Retroperitoneoscopic living donor nephrectomy: two cases. *Transplant Proc* 1994; 26(4): 2409.
9. Clayman RV, Soper NJ, Dierks SM, et al. Laparoscopic nephrectomy [Letter]. *N Engl J Med* 1991; 325(15): 1110.
10. Weinstein SH, Navarre RJ, Loening SA, Corry RJ. Experience with live donor nephrectomy. *J Urol* 1980; 124: 321.
11. Riehle RA, Steckler R, Naslund EB, Riggio R, Cheigh J, Stubenbord W. Selection criteria for the evaluation of living related renal donors. *J Urol* 1990; 144: 845.
12. United Network for Organ Sharing. UNOS update. Richmond, VA: UNOS, 1994; 10(2): 29.
13. Bay WH, Hebert LA. The living donor in kidney transplantation. *Ann Int Med* 1987; 106: 719.

Received 9 March 1995.

Accepted 30 May 1995.

