

Johns Hopkins University/Library
Service Center Interlibrary Loan



LSC TN: 1540141

Borrower: WELCH

Lending String: LSC

Patron:

Journal Title: Trans of Amer Assoc of
Genito-urinary Sugeons

Volume: 55 **Issue:**
Month/Year: 1963**Pages:** 7-12

Article Author: King LR, Mellins HZ,
Scott WW

Article Title: Radiographic Evaluation of
the Bladder Neck in Childhood

Imprint:

ILL Number: 1540129



LOCATION: LSC

BAR CODE:

RMST #: R10M14S26T12 261+

Borrower: WELCH
7/28/2014 2:48:19 PM

Charge
Maxcost:

Shipping Address:
Welch Medical Library
LOCAL

Fax:
Ariel:
Email: weldoc@lists.jhmi.edu
ODYSSEY IP: illiad.library.jhu.edu



RADIOGRAPHIC EVALUATION OF THE BLADDER NECK IN CHILDHOOD

LOWELL R. KING,* HARRY Z. MELLINS† AND WILLIAM WALLACE SCOTT

From the James Buchanan Brady Urological Institute, The Johns Hopkins Hospital, Baltimore, Md.

Voiding cinecystourethrograms were performed on 121 pediatric patients who were between 1 day and 17 years of age. Virtually all pediatric patients seen in consultation by any of the authors between September 1962 and April 1963 were evaluated by this method. This review correlates the radiographic appearance of the bladder neck with clinical diagnosis or operative findings. Particular attention is given to evaluation of the appearance of the bladder neck in patients with obstruction distal to the bladder neck.

MATERIALS AND METHOD

Voiding cystourethrography was performed as early as 1 day after birth. After cleaning the external urinary meatus with an antiseptic, 2 to 5 cc of a water-soluble anesthetic lubricating jelly was injected into the urethra using a syringe with a blunt tip. A few minutes later, a catheter was inserted and the amount of residual urine was determined. A dual lumen catheter, made by gluing two 6F polyvinyl catheters together, was used in all girls and in all boys whose urethras were large enough to permit passage of the catheter. The open ends of the polyvinyl catheters were 2 cm. apart in the model used for girls, and 5 cm. apart in the model used for boys. The catheter tips were radiopaque and could be placed above and below a possible obstruction. Simultaneous pressures above and below the point of obstruction could be determined during voiding by connecting the catheters to strain gauges. During bladder filling, both catheter ends were in the bladder, and as the bladder was filled through one lumen with 15 per cent hypaque from a reservoir 30 inches above the pubis, a cystometrogram was obtained through the other. Bladder filling was observed fluoroscopically, using a television camera image intensifier system. When vesicoureteral reflux was observed during filling, the bladder pressure and volume at which this occurred were noted. Filling was continued

until the patient complained of extreme fullness or, in infants, until voiding around the catheters began. Pressures were recorded simultaneously in the bladder and distal urethra in the female, and in the bladder and bulbous urethra in the male. These results will be the subject of a future communication. The bladder was then refilled with 15 per cent hypaque and the catheters were removed before voiding began. Voiding was observed fluoroscopically, and the output screen of the image intensifier was photographed directly. During voiding, the antero-posterior (AP) view and the true lateral views were observed. The bladder was refilled when necessary to obtain both views. All studies were done by the same examiners using the technique just outlined.

For the purpose of evaluating the bladder neck, we have excluded the cases of children with neurogenic bladder due to meningomyelocele (8 patients) or other causes (2 patients), uropathy associated with absent abdominal muscles (2 patients), epispadias (1 patient), and those in whom voiding cystourethrography was initially performed after transurethral resection (1 patient), Y-V plasty (3 patients) or closure of bladder exstrophy (1 patient). This left 103 patients for evaluation of whom 46 were girls and 57 were boys.

A radiographic appearance of the bladder neck and proximal urethra was noted in the antero-posterior (AP) and lateral view. This appearance was later correlated with the patient's course and clinical diagnosis. In the AP view, the internal urethral orifice was approximately the same diameter as the proximal urethra in some instances (fig. 1); at times the bladder neck was wider than the urethra below it, and at times the bladder neck was narrower than the proximal urethra (fig. 2). Similarly, in the lateral view, the bladder neck sometimes appeared to be of the same caliber as the urethra immediately below it, but in some instances the bladder neck was narrowed by a filling defect arising from the anterior (fig. 3) or posterior (fig. 4) wall at the level of the internal sphincter, and the proximal urethra then appeared relatively wide.

* Present address: Children's Memorial Hospital, Chicago 14, Ill.

† Present address: Department of Radiology, Downstate Medical Center, State University of New York, Brooklyn, N. Y.

The occurrence of each type of configuration was noted, and is correlated below with the clinical diagnosis.

RESULTS

Cinecystourethrograms were performed on 46 girls. Thirty-two of these patients were evaluated because of urinary tract infection, and though

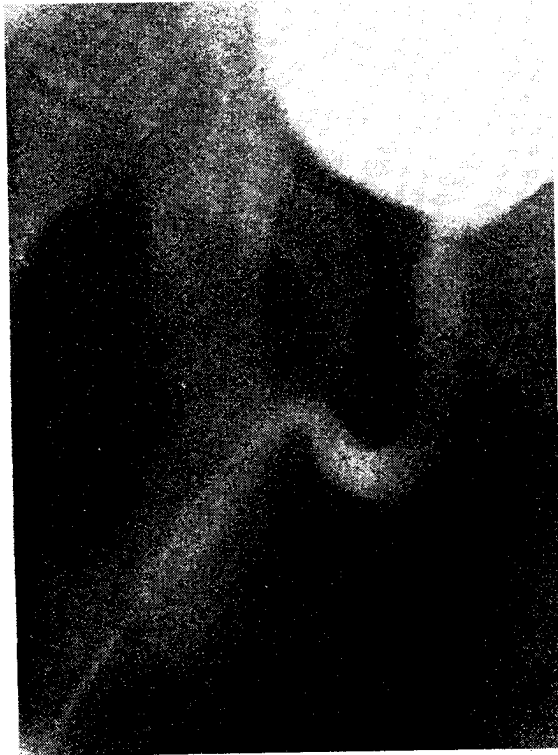

FIG. 1. Voiding cystourethrogram, antero-posterior view, in boy presenting with enuresis. Note walls of prostatic urethra are parallel and vesical neck is of approximately same caliber as prostatic urethra. Also note narrow stream distal to meatal stenosis.

three were thought to have meatal stenosis on clinical grounds alone, none had unequivocal primary bladder neck obstruction. Ten had some degree of vesicoureteral reflux, but in only one of these was the reflux associated with a para-ureteral bladder diverticulum and urethral obstruction (meatal stenosis). In 14 (43.8 per cent) the bladder neck was narrower than the proximal urethra on voiding cystourethrogram, but reflux was no more common in this group than in those in whom the bladder neck appeared open on the AP view (table 1). Fourteen girls who presented without urinary tract infection and whose lower urinary tracts were thought to be normal had a similar incidence (6 or 42.8 per cent) of bladder necks which were narrow, relative to the proximal urethra (table 2). This finding, therefore, is common in girls with and without urinary tract infection, and is certainly not pathognomonic of primary bladder neck obstruction.

An anterior filling defect in the region of the bladder neck as seen in the lateral view is possibly due to incomplete relaxation of the internal sphincter. This is seen more often in the presence of infection (47 per cent) than without infection (35.7 per cent), but this difference is not significant. This finding is commonly associated with a bladder neck which appears narrow, relative to the proximal urethra when seen on the AP view. Although an anterior filling defect as seen on voiding cystourethrogram may occasionally be found in a patient with bladder trabeculation or residual urine (2 patients), the majority are not associated with objective signs of bladder outlet obstruction.

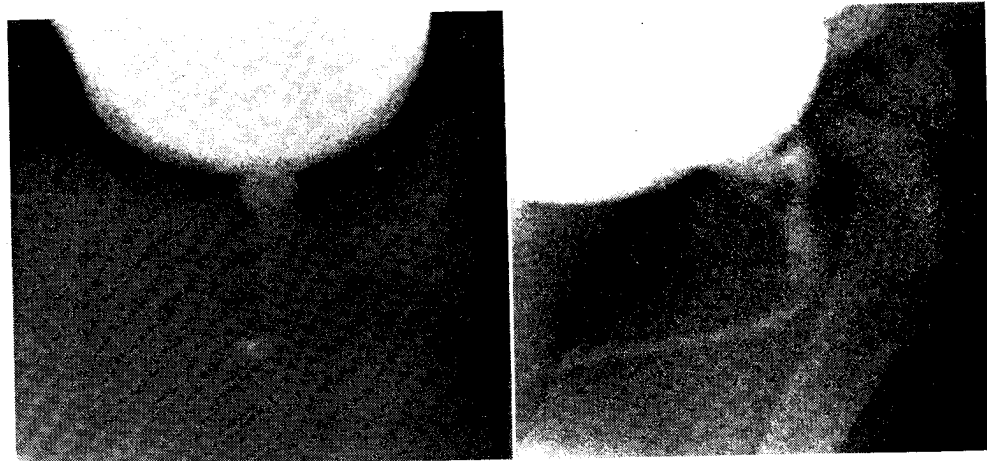


FIG. 2. Boy presenting with urinary tract infection, residual urine and vesicoureteral reflux. Note posterior filling defect in bladder neck on lateral view and relatively narrow bladder neck relative to prostatic urethra on antero-posterior view. This patient had primary bladder neck obstruction and is improved after vesical neck Y-V plasty.

FIG. in girl prior fil obstru

No ref
Bladd
uret
Bladd
With
Bladd
uret
Bladd

Total

Tw
filling
neck
obstru
perio
tions:
spite
a sub
worth
narro
of the
Vo

al stenosis on
l unequivocal
Ten had some
t in only one
with a para-
urethral ob-
43.8 per cent)
i the proximal
um, but reflux
than in those
d open on the
who presented
l whose lower
normal had a
nt) of bladder
o the proximal
therefore, is
urinary tract
ognomonic of

region of the
view is possi-
of the internal
n the presence
hout infection
is not signifi-
ociated with a
w, relative to
the AP view.
it as seen on
asionally be
trabeculation or
pority are not
bladder outlet

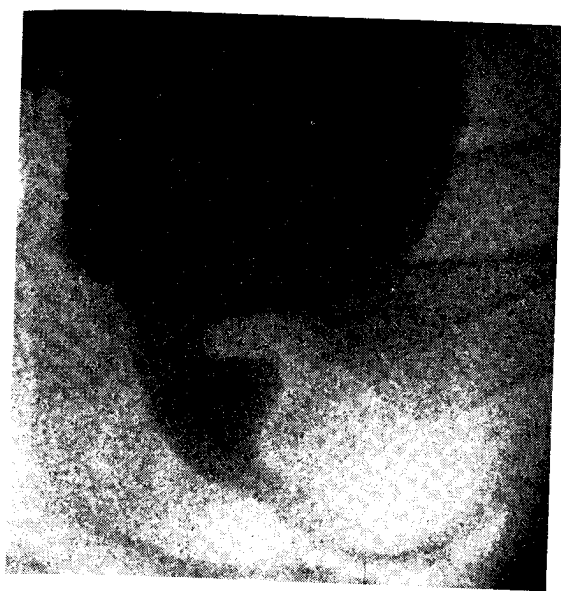


FIG. 3. Lateral view voiding cystourethrogram in girl presenting with enuresis. Note large anterior filling defect at bladder neck. No anatomical obstruction was found.

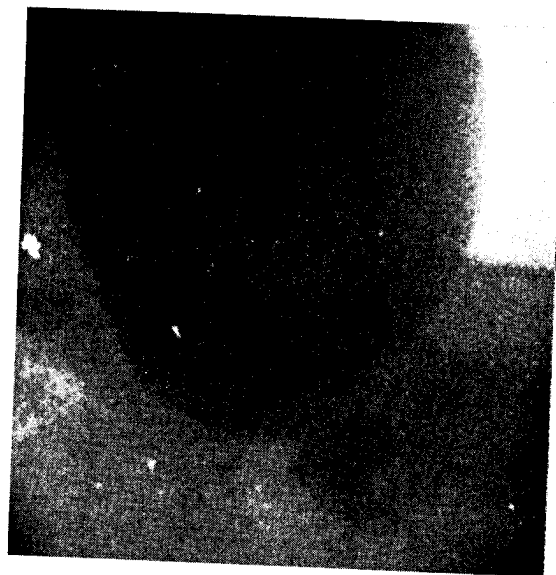


FIG. 4. Lateral view cystourethrogram in girl presenting with urinary tract infection. Note anterior and posterior filling defects at bladder neck. This patient requires urethral dilatation monthly to prevent recurrent urinary tract infection.

TABLE 1. Girls presenting for urological evaluation with urinary tract infection (32 patients). Appearance of bladder neck in voiding cystourethrogram

AP View	Lateral View		
	Anterior filling defect at level of bladder neck	Anterior and posterior filling defect at bladder neck	Wide bladder neck in lateral view
<i>No reflux</i> (22 patients):			
Bladder neck appears narrow with relatively wide proximal urethra.....			
Bladder neck appears as wide or wider than proximal urethra....	6	2	2
<i>With reflux</i> (10 patients):			
Bladder neck appears narrow with relatively wide proximal urethra.....			
Bladder neck appears as wide or wider than proximal urethra....	2		2
	1		5
Total.....	15	2	15

Two girls in whom an anterior *and posterior* filling defect appeared at the level of the bladder neck during voiding have an objective sign of obstruction (bladder trabeculation). One requires periodic urethral dilatation to prevent reinfections; the other has had repeated infections in spite of dilatations, and requires maintenance on a sulfa drug to keep the urine sterile. It is noteworthy that both of these girls had a relatively narrow internal urinary meatus on the AP view of the cystourethrogram also.

Voiding cystourethrograms were performed on

57 boys. Five were found to have primary obstructions of the bladder neck, evidenced by residual urine, vesicoureteral reflux and bladder trabeculation in the absence of urethral valves or strictures or meatal stenosis. Four of these five presented with urinary tract infection, and three were azotemic. One boy was treated by urinary diversion; three improved pyelographically after plastic enlargement of the bladder neck and the fourth is yet to be treated. In each instance, a posterior filling defect could be seen at the level of the bladder neck on the lateral view of the

al reflux. Note
neck relative to
ruction and is

voiding cystourethrogram (fig. 2). One patient had an anterior filling defect on the same view. Four of the five boys exhibited a narrow bladder neck with respect to the prostatic urethra in the AP view.

Seventeen boys were seen in whom an obstruction was present in the urethra distal to the bladder neck. Eight of these had meatal stenosis which was clinically evident and/or produced dilatation of the urethra upon voiding; six had a type 3 (iris) valve and three had a type 1 (leaflet)

valve in the posterior urethra producing at least some degree of dilatation of the proximal urethra. The configuration of the bladder neck in these patients is given in table 3. It is noteworthy that eight of these 17 patients had a posterior filling defect in the bladder neck (fig. 5), whereas none of the boys without infection or distal urethral obstruction had this filling defect (table 4). The posterior filling defect in these patients is thought to represent a contracture of the bladder neck secondary to distal obstruction (valve or meatal stenosis) (fig. 5). The 17 patients with primary obstruction distal to the bladder neck also exhibited anterior filling defects in the bladder neck on the lateral view (8 of 17); and narrow bladder necks relative to the prostatic urethra on the AP view (11 of 17). These findings were present in normal boys also, although the incidence in normals was lower (table 4).

Twenty-three boys presented with urinary tract infection, and of this group, 13 were found to have bladder outlet obstruction (type 3 valve, 4; type 1 valve, 2; primary bladder neck obstruction, 4; meatal stenosis, 2; and ectopic ureterocele producing bladder neck obstruction, 1). Eight of the 10 without outlet obstruction had a bladder neck which appeared open on both AP and true lateral views. One of the remainder without demonstrable outlet obstruction had a narrow bladder neck relative to the prostatic urethra in the AP view only, and one had a narrow bladder neck in the AP view with a filling defect in the region of the bladder neck anteriorly in the lateral view.

TABLE 2. Girls presenting for urological examination without urinary tract infection (14 patients). Evaluation of bladder neck by voiding cystourethrogram

AP View	Lateral View	
	Anterior filling defect at level of bladder neck	Wide bladder neck in lateral view
Bladder neck appears narrow with relatively wide proximal urethra	4	2
Bladder neck appears as wide or wider than proximal urethra	1	7
Total	5	9

Eight of the above patients presented with enuresis, two because of failure to thrive, and one each with diurnal incontinence, glomerulonephritis, hypertension and renal osteodystrophy. None had demonstrable vesicoureteral reflux.

TABLE 3. Characterization of the bladder neck by voiding cystourethrogram in boys with demonstrable urethral obstruction distal to the bladder neck (17 patients)

AP View	Lateral View			
	Anterior filling defect at level of bladder neck	Posterior filling defect at level of bladder neck	Anterior and posterior filling at level of bladder neck	Wide bladder neck
Bladder neck appears narrow with relatively wide proximal urethra	7	1	3	0
Bladder neck appears as wide or wider than proximal urethra	1	4	0	1
Total	8	5	3	1

Eight of these patients had meatal stenosis, six had type 3 (iris) valves, and three had type 1 (leaflet) valves.

Fi
ral v
tatic

TABLE

Blad
pr
Blad
ure

Tota
.
tion,

In
ureth
assoc
poste
neck
This
prim
usual
relati
AP v
ever,
dema
there
struc
defec

cing at least mal urethra. eck in these worthy that sterior filling whereas none stal urethral able 4). The ts is thought ladder neck ve or meatal ith primary eck also ex- bladder neck row bladder ra on the AP re present in incidence in

with urinary 3 were found on (type 3 bladder neck and ectopic obstruction, obstruction open on both he remainder action had a the prostatic l one had a with a filling eck anteriorly

demonstrable

inding of eck	Wide bladder neck
	0
	1
	1

type 1 (leaflet)

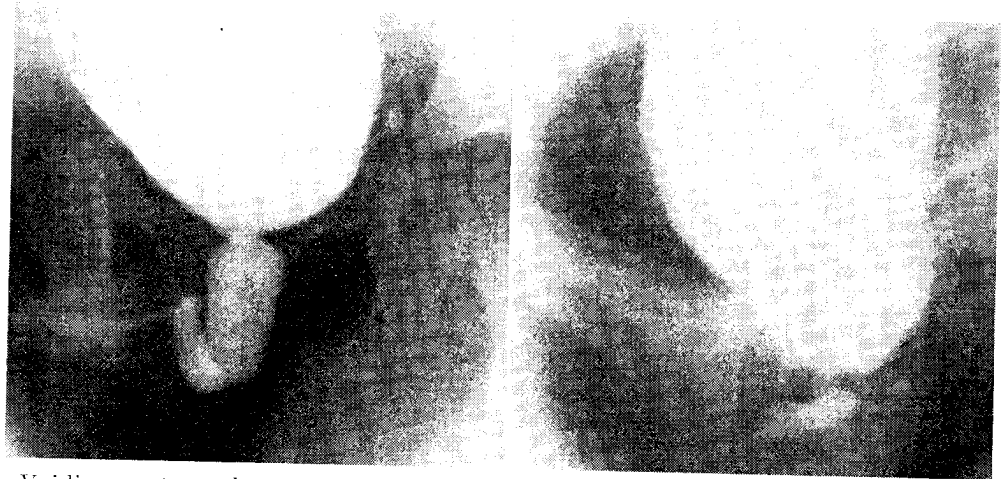


FIG. 5. Voiding cystourethrogram in boy who presented with urinary tract infection. Note urethral valve (type 1) causing dilatation of prostatic urethra. Note also narrow bladder neck relative to prostatic urethra on antero-posterior view and anterior and posterior filling in bladder neck on lateral view.

TABLE 4. Characterization of the bladder neck by voiding cystourethrogram in boys without urinary tract infection, and excluding those with urethral obstruction distal to the bladder neck (24 patients)

AP View	Lateral View			
	Anterior filling defect at level of bladder neck	Posterior filling defect at level of bladder neck	Anterior and posterior filling defects at level of bladder neck	Wide bladder neck
Bladder neck appears narrow with relatively wide proximal urethra.....	3	1*	0	2
Bladder neck appears as wide or wider than proximal urethra.....	2	0	0	16
Total.....	5	1	0	18

* This patient had primary bladder neck obstruction, evidenced by vesicoureteral reflux, trabeculation, and residual urine.

DISCUSSION

In evaluation of 46 girls by voiding cystourethrograms, the only radiographic sign clearly associated with bladder neck obstruction was a posterior filling defect at the level of the bladder neck seen on the full lateral view (2 patients). This sign was also present in 5 boys who had primary obstruction of the bladder neck, and was usually associated with a narrow bladder neck relative to the proximal urethra as seen in the AP view. The narrow neck on the AP view, however, was commonly seen in the absence of demonstrable anatomical obstruction and is, therefore, unreliable as a sign of bladder neck obstruction. On the other hand, posterior filling defects at the level of the bladder neck as seen on

the lateral view were always associated with obstructive lesions, in 7 instances with primary bladder neck obstruction and in 8 boys with urethral obstruction distal to the bladder neck (meatal stenosis or valve). In these 8 boys, a true contracture of the bladder neck is thought to be present, caused by the generalized detrusor hypertrophy secondary to the more distal obstruction. The posterior filling defect at the bladder neck is, therefore, indicative of contracture, but may occur in primary or secondary bladder neck hypertrophy. If urethral valves, stricture, and meatal stenosis can be excluded, the posterior filling defect is a reliable sign of primary bladder neck contracture.

An anterior filling defect in the bladder neck

as seen on the lateral view of a voiding cystourethrogram is probably due to incomplete relaxation of the internal sphincter and, to our knowledge, is of no clinical significance.

SUMMARY

One hundred and three voiding cinecystourethrograms were reviewed to see what radiographic appearance, if any, was characteristic of bladder neck contracture. Posterior filling defects in the bladder neck seen in the lateral view are consistently present in bladder neck contracture, whether primary or secondary to an obstruction more distally situated in the urethra.

A narrow bladder neck relative to the proximal urethra as seen in the AP view is a common finding, and is certainly not a specific sign of bladder neck contracture.

REFERENCES

- AMBROSE, S. S. AND NICOLSON, W. P., III: The causes of vesicoureteral reflux in children. *J. Urol.*, **87**: 688-694, 1962.
- BENJAMIN, J. A.: Use of cinematography in urological studies. *J. Urol.*, **81**: 227-231, 1959.
- BODIAN, M.: Congenital bladder neck obstruction. *Brit. J. Urol.*, **29**: 393, 1957.
- FISHER, O. D. AND FORSYTHE, W. L.: Micturating cystourethrography in the investigation of enuresis. *Arch. Dis. Childhood*, **29**: 460-471, 1954.
- GARRETT, R. A., RHAMY, R. K. AND CARR, J. R.: Non-obstructive vesicoureteral regurgitation. *J. Urol.*, **87**: 350-354, 1962.
- GLEASON, D. M. AND LATTIMER, J. K.: The pressure-flow study: A method for measuring bladder neck resistance. *J. Urol.*, **87**: 844-852, 1962.
- KJELLBERG, S. R., ERICSSON, N. O. AND RUDHE, U.: *The Lower Urinary Tract in Childhood*. Chicago: The Year Book Publishers, Inc., 1957.
- LAPIDES, J.: Introduction to Section on Micturition. In: *The Year Book of Urology, 1960-61* series, p. 250. Chicago: The Year Book Publishers, Inc.
- LEADBETTER, G. W. AND LEADBETTER, W. F.: Diagnosis and treatment of congenital bladder-neck obstruction in children. *New Eng. J. Med.*, **260**: 633-637, 1959.
- LICH, R. JR., HOWERTON, L. W. AND DAVIS, L. A.: Recurrent urosepsis in children. *J. Urol.*, **86**: 554-558, 1961.
- LICH, R. JR., HOWERTON, L. W. AND DAVIS, L. A.: Vesicourethrography. *J. Urol.*, **85**: 396-397, 1961.
- LOW, J. A.: Role of normal female urethra in the sphincter mechanism of the bladder. *Am. J. Obst. Gynec.*, **82**: 1-9, 1961.
- MURPHY, J. J. AND SCHOENBERG, H.: Observations on intravesical pressure changes during micturition. *J. Urol.*, **84**: 106-110, 1960.
- NESBIT, R. N. AND BAUM, W. C.: Diagnosis and surgical management of obstructive uropathy in childhood. *A.M.A. Am. J. Dis. Child.*, **88**: 239, 1954.
- NUNN, I. N. AND STEPHENS, F. D.: The triad syndrome: A composite anomaly of the abdominal wall, urinary system and testes. *J. Urol.*, **86**: 782-794, 1961.
- PAQUIN, A., MARSHALL, V. F. AND MCGOVERN, J. H.: The megacystis syndrome. *J. Urol.*, **83**: 634-646, 1960.
- PRESMAN, D.: Congenital valves of the posterior urethra. *J. Urol.*, **86**: 602-611, 1961.
- RAPER, F. P.: The recognition and treatment of congenital urethral valves. *Brit. J. Urol.*, **25**: 136-141, 1953.
- SANDOE, E., BRYNDORF, J. AND GERTZ, T. C.: Cystometry. A new technique applying a percutaneously inserted catheter in the bladder. *Danish Med. Bull.*, **6**: 194, 1959.
- SPENCE, H. M., STEWART, C. M., MARSHALL, V. F., LEADBETTER, W. F. AND HUTCH, J. A.: Panel discussion on ureteral reflux in children. *J. Urol.*, **85**: 119-144, 1961.
- STEPHENS, F. D.: Treatment of megaureters by multiple micturition. *Austral. & New Zealand J. Surg.*, **27**: 130-134, 1957.
- STEPHENS, F. D.: Urethral obstruction in childhood: Use of urethrography in diagnosis. *Austral. & New Zealand J. Surg.*, **25**: 89-109, 1955.
- STEPHENS, F. D. AND LENAGHAN, D.: The anatomical basis and dynamics of vesicoureteral reflux. *J. Urol.*, **87**: 669-680, 1962.
- STEWART, C. M.: Congenital bladder neck obstruction. *J. Urol.*, **83**: 679-681, 1960.
- WATERHOUSE, K. AND HAMM, F. C.: The importance of urethral valves as a cause of vesical neck obstruction in children. *J. Urol.*, **87**: 404-408, 1962.
- WATERHOUSE, K. AND SCORDAMAGLIA, L. J.: Anterior urethral valve. A rare cause of bilateral hydronephrosis. *J. Urol.*, **87**: 556-559, 1962.
- WILLIAMS, D. I.: Megacystis and megaureter in children. *Bull. N. Y. Acad. Med.*, **35**: 317-327, 1959.
- WOLGIN, W., ROSENBERG, M. AND MUSCHAT, M.: Co-existence of congenital median bar and urethral valves. *J. Urol.*, **68**: 506, 1952.
- YOUNG, H. H., FRONTZ, W. A. AND BALDWIN, J. C.: Congenital obstruction of the posterior urethra. *J. Urol.*, **3**: 289, 1919.
- YOUNG, H. H. AND MCKAY, R. W.: Congenital valvular obstruction of the posterior urethra. *Surg., Gynec. & Obst.* **48**: 509, 1929.