

PROSTATIC CANCER

Further Investigation of Hormonal Relationships

HERBERT BRENDLER, M.D.

NEW YORK

WILLIAM E. CHASE, M.D.

AND

WILLIAM WALLACE SCOTT, M.D.

BALTIMORE

IN 1941 research in prostatic cancer received great impetus from the discovery by Huggins and his associates¹ that remarkable regression occurred clinically in the primary neoplasm and its metastases after castration or administration of estrogen. These findings were subsequently verified by others.² Unfortunately, the gratifying improvement manifested by most patients treated in this manner has since been found to be only temporary, and no actual cures have ever been recorded. Furthermore, postmortem studies on patients in whom no palpable or roentgenologic evidence of local or distant recurrence was evident just before death have shown extensive involvement of the prostate, bones and soft tissues. In all cases in which radical perineal prostatectomy has been done for advanced cancer after preoperative administration of

From the James Buchanan Brady Urological Institute, Johns Hopkins Hospital, Baltimore.

Read before the Section on Urology at the Ninety-Eighth Annual Session of the American Medical Association, Atlantic City, N. J., June 10, 1949.

This work was supported in part by the American Cancer Society's institutional grant to the Johns Hopkins University School of Medicine and in part by a grant from the National Brewing Company.

1. Huggins, C., and Hodges, C. V.: Studies on Prostatic Cancer: I. The Effect of Castration, of Estrogen and of Androgen Injection on Serum Phosphatases in Metastatic Carcinoma of the Prostate, *Cancer Research* **1**:293, 1941. Huggins, C.; Stevens, R. E., and Hodges, C. V.: Studies on Prostatic Cancer: II. The Effect of Castration on Clinical Patients with Carcinoma of the Prostate, *Arch. Surg.* **43**:209 (Aug.) 1941. Huggins, C.; Scott, W. W., and Hodges, C. V.: Studies on Prostatic Cancer: III. The Effects of Fever, of Desoxycorticosterone and of Estrogen on Clinical Patients with Metastatic Carcinoma of the Prostate, *J. Urol.* **46**:997, 1941.

2. Herbst, W. P.: The Effects of Estradiol Dipropionate and Diethylstilbestrol on Malignant Prostatic Tissue, *Tr. Am. A. Genito-Urin. Surgeons* **35**:195, 1941. Alyea, E. P., and Henderson, A. F.: Carcinoma of the Prostate: Immediate Response to Bilateral Orchiectomy: Clinical and X-Ray Evidence, *J. A. M. A.* **120**:1099 (Dec. 5) 1942.

estrogen, malignant cells have been readily demonstrated in the surgical specimens.³ We have thus been forced to conclude that although existing methods of endocrine manipulation have undoubtedly been of real benefit in the majority of patients so far as their symptoms were concerned they have not provided the final answer.

At present the effectiveness of castration or estrogen therapy in disseminated prostatic cancer is measured by certain subjective and objective criteria. Many of these criteria are confusing. For example, serum acid phosphatase levels are normal in approximately 35 per cent of cases of widespread prostatic cancer. Frequently we fail to observe lowering of increased serum acid phosphatase values after castration or administration of estrogen. Increase of a previously normal acid phosphatase value has been observed immediately after castration. Thus, though trends can be demonstrated, unidirectional changes are not consistent. These minority changes may be important.

Initially, when the investigation of hormonal relationships in prostatic cancer was being continued, it seemed appropriate to reconsider the original premise on which recent hormonal management is based. We refer to Huggins' concept that prostatic cancer is an overgrowth of adult prostatic epithelial cells and that adult prostatic epithelial cells undergo atrophy when androgens are reduced by castration or inactivated by estrogen administration. Wide acceptance of the thesis that androgens must be removed, neutralized or destroyed led Huggins and his associates, as well as others, to search for sources of androgen in organs other than the testes and for ways of removing, neutralizing or destroying them.

That the adrenal gland is an extragonadal source of androgens seems clear, both in animals and in man. However, in a study by Huggins and Scott,⁴ in which they surgically removed the adrenals in a patient previously castrated for prostatic cancer, the tumor at autopsy was widely disseminated in spite of evidence, based on urinary assays, that body androgens were low. On this evidence they postulated that certain prostatic cancers were independent of androgen.

It appears to us that if continued progress is to be made in the treatment of prostatic cancer, the exact role of androgens in the induction of cancer or the maintenance of cancer growth must be ascertained. If androgen dependence is all-important, other means of eliminating

3. Colston, J. A. C., and Brendler, H.: Endocrine Therapy in Carcinoma of the Prostate: Preparation of Patients for Radical Perineal Prostatectomy, *J. A. M. A.* **134**:848 (July) 1947.

4. Huggins, C., and Scott, W. W.: Bilateral Adrenalectomy in Prostatic Cancer: Clinical Features and Urinary Excretion of 17-ketosteroids and Estrogen, *Ann. Surg.* **122**:1031, 1945.

androgens must be explored. If other factors exist, these in turn must be investigated.

We wish to present a report of our clinical findings in a long range study of hormonal relationships in prostatic cancer, in which the effects of androgens were studied. For this purpose we placed under observation a selected group of patients with advanced carcinoma of the prostate. A survey was made of a large number of persons with the disease. Before we embarked on a full scale study project, 3 of these patients, for whom the prognosis was regarded as hopeless, were chosen for preliminary study. After their immediate status had been ascertained by means of rectal palpation, roentgenograms of the bones and serum acid phosphatase assays, each patient received a 200 mg. pellet of testosterone propionate, implanted subscapularly. At regular intervals the patients were seen in the dispensary and reevaluated. Because of the qualitative

TABLE 1.—*Classification Code for Patients with Prostatic Cancer*

-
- | | |
|----|---|
| 1. | Rectal findings |
| a. | Limited to gland proper |
| b. | Beyond the gland proper |
| 2. | Presence of osseous deposits |
| 3. | Increase of serum acid phosphatase |
| 4. | Histologic classification (of most malignant area) |
| a. | Well differentiated |
| b. | Poorly differentiated |
| c. | Anaplastic |
| d. | Other (including extension or metastasis to the prostate) |
| 5. | Prior treatment (whether diagnosed as cancer or not) |
| a. | Endocrine (including castration, use of estrogen, etc.) |
| b. | Surgical |
| c. | Irradiation |
| d. | Chemotherapeutic |
| e. | Other |
-

nature of this preliminary study, no attempt has been made to tabulate or plot the changes which were observed. It is fair to state, however, that 2 of the patients improved considerably within two weeks from a symptomatic standpoint, and in 1 of these there was a palpable decrease in the size of the prostate. The improvement in this patient lasted for about five months, at which time symptoms returned. He was given testosterone linguets,⁵ 6.0 mg. daily, and again he improved. The third patient treated by implantation of pellets was somewhat worse during the first week but then returned to his former state, apparently none the worse.

Because of these surprising, but not totally unexpected, observations, a planned program of investigation was begun. By means of a careful screening process (table 1), 3 patients with advanced prostatic cancer

5. Dr. J. Murray Scott, of Ayerst, McKenna & Harrison, Ltd., gave us a generous supply of 6 mg. lingusorbs[®] of testosterone and Dr. Edward Henderson, of the Schering Corporation, the testosterone propionate used.

were admitted to the hospital and preliminary studies carried out (table 2). In each case biopsy of material from the prostate was done perineally and the histologic diagnosis established. After complete evaluation, the patients were given daily injections of 25 mg. of testosterone propionate in sesame oil. Follow-up studies were made periodically according to plan (table 3). These results were subjected to frequent analysis, and whenever indicated, changes were made in the plan of treatment, as will be seen in the case histories and figures to follow.

TABLE 2.—*Initial Studies*

-
-
1. Basic (complete blood count, urinalysis, nonprotein nitrogen, carbon dioxide, sugar, chlorides, sodium, potassium, calcium, cholesterol, icteric index, proteins, liver function tests, kidney function tests, etc.)
 2. Total neutral 17-ketosteroids
 3. Other hormonal studies (androgen, estrogen and follicle-stimulating hormone)
 4. Serum enzyme studies, including acid and alkaline phosphatase and glucuronidase
 5. Flat roentgenogram and intravenous urogram, roentgenograms of bones
 6. Roentgenogram of chest
 7. Cystoscopy
 8. Touch pictures
 9. Perineal biopsy of prostate
 10. Sternal biopsy
 11. Biopsy of testis
-

TABLE 3.—*Plan of Action*

-
-
1. Testosterone propionate in sesame oil, 25 mg. daily
 2. Basic weekly laboratory studies
 3. Total neutral 17-ketosteroids twice weekly
 4. Serum enzymes studies daily
 5. Roentgenograms of bones every 2 weeks
 6. Cystoscopy as indicated
 7. Touch pictures weekly
 8. Repeat biopsies of prostate, sternum and testis
 9. Other hormonal studies as indicated
-

REPORT OF CASES

CASE 1.—L. S., a white man aged 65, was admitted to the hospital on Jan. 17, 1949. A diagnosis of metastatic prostatic cancer had been made elsewhere in 1946 and bilateral orchiectomy performed. Shortly thereafter he received high voltage roentgen ray therapy to the pelvis. Estrogen therapy had been initiated after orchiectomy and continued until the patient's admission. These measures had afforded little relief. On his admission, he complained of severe generalized pain, was found to be in an extreme state of inanition and weakness and was almost moribund. The prostate was small and soft, without evidence of nodularity or fixation. Preliminary studies showed marked anemia, hypoproteinemia, a total 17-ketosteroid excretion of 3.0 mg. per day, a serum acid phosphatase level of 27.9 units and a serum alkaline phosphatase of 25.9 units.⁶ Multiple roentgenograms of the bones revealed diffuse osteoblastic metastasis. Perineal biopsy of the pros-

6. Acid and alkaline serum phosphatase levels are expressed in King-Armstrong units.

tate revealed a moderately differentiated adenocarcinoma. Sternal biopsy showed extensive involvement of the marrow with prostatic cancer.

On the eleventh day (fig. 1) injections of testosterone, 25 mg. daily, were begun. After the first week there was less pain, with increased appetite and a gain in weight. Periodic rectal examinations disclosed no appreciable change in the prostate. The hemoglobin content rose from 9 to 12 Gm. per hundred cubic centimeters. As expected, the urinary 17-ketosteroids gradually rose. The serum acid phosphatase rose to 82 units by the twentieth day, and a slight transient rise in the alkaline phosphatase also occurred. On the twenty-fifth day the dose of testosterone propionate was increased to 50 mg. per day, and the urinary steroids and serum acid and alkaline phosphatase levels showed further generalized increases. At this time, the patient's general condition was much improved. On the fortieth day administration of testosterone was increased to 100 mg. daily and maintained at this level until the seventieth day, when it was discontinued. Within fourteen days the acid phosphatase had fallen to 22 units. At approximately the hundredth

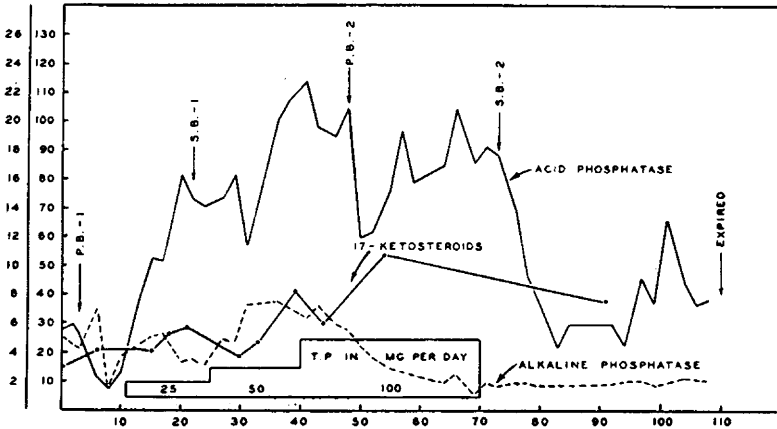


Fig. 1 (case 1).—Ordinates, 17-ketosteroids in milligrams per day (0 to 26); acid and alkaline serum phosphatase (0 to 130 units). Abscissa, days. P. B.-1 and P. B.-2 represent perineal biopsies; S. B.-1 and S. B.-2 represent sternal biopsies.

day his condition changed for the worse, and three days later he died. During this terminal stage the acid phosphatase rose, reaching 67.3 units on one occasion.

Shortly after the dosage of testosterone was increased to 100 mg. daily, we had observed generalized bronzing of the skin, most marked over the head, neck and chest. This resembled Addisonian pigmentation and led us to suspect alteration in adrenal function secondary to either metastatic involvement or administration of testosterone. On the seventieth day thrombopenic purpura had developed, thought to be secondary to extreme involvement of the bone marrow with tumor. This condition persisted until death.

Studies of perineal and sternal biopsies made before and after administration of testosterone revealed no striking alterations in the histologic pattern of the tumor. Serial roentgen studies showed no significant changes in the bones.

CASE 2.—W. S., a white man aged 69, was admitted to the hospital on Jan. 20, 1949, complaining of moderately severe urinary frequency, slight diminution in the size and force of the voided stream and a weight loss of 60 pounds (27.2 Kg.) during the previous year. On rectal examination the prostate was enlarged, nodular

and stony hard, with evidence of extension into the left seminal vesicle and peri-prostatic tissues.

Preliminary studies showed moderate anemia, increased sedimentation rate, with a normal white blood cell count, a urinary 17-ketosteroid level of 4.0 mg. per day and a serum acid phosphatase value of 28.2 units. Roentgenograms of the skeleton revealed generalized osteoblastic metastasis. Perineal biopsy of the prostate disclosed adenocarcinoma. Sternal biopsy showed metastatic carcinoma.

On the twelfth day (fig. 2) injections of testosterone, 25 mg. daily, were begun. This dosage schedule was maintained until the fifty-fifth day when it was increased to 100 mg. daily. On the seventieth day administration of testosterone was discontinued.

During this time, the patient's condition improved somewhat. His appetite increased, and he gained weight. There was no essential change in the rectal findings. The urinary 17-ketosteroids fluctuated widely. The serum acid phos-

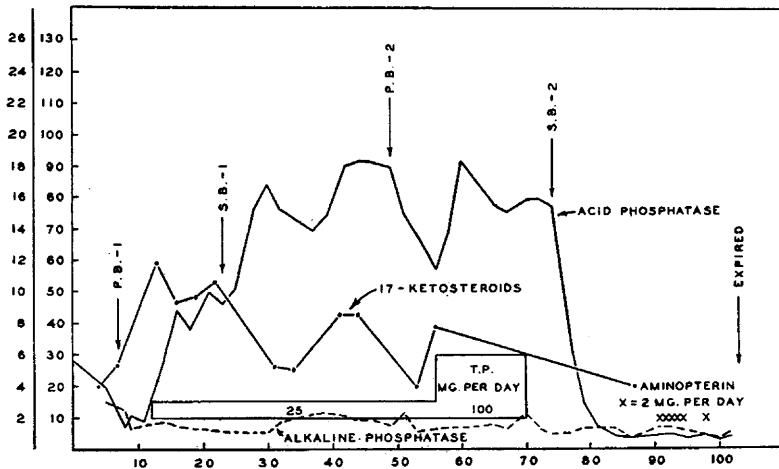


Fig. 2 (case 2).—Ordinates, 17-ketosteroids in milligrams per day (0 to 26); acid and alkaline serum phosphatase (0 to 130 units). Abscissa, days. P. B.-1 and P. B.-2 represent perineal biopsies; S. B.-1 and S. B.-2 represent sternal biopsies.

phatase level rose promptly after testosterone was given and remained increased until shortly after administration of the drug was stopped. In contrast to case 1, the alkaline phosphatase showed little change. Within three weeks after injections of testosterone were discontinued the patient began to suffer a loss of appetite and weight and was confined to bed. However, at no time did he suffer pain in the bones.

From the ninety-first day, in an effort to alter his downhill course, the patient was given daily injections of 2 mg. of aminopterin® (4-aminopteroylglutamic acid), a folic acid antagonist. Five days later hemorrhagic manifestations developed, and the use of the drug was discontinued. On the one hundred and third day he died.

In contrast to case 1, definite histologic changes were noted in prostatic and sternal biopsies. Although the over-all pattern remained the same, the individual cells became swollen, the cytoplasm vacuolated and the nuclei more deeply stained.

On roentgen examination there were no changes in the character or extent of osseous metastasis.

CASE 3.—W. C., a Negro aged 72, was admitted to the hospital on Feb. 5, 1949. During the previous year he had experienced increasing urinary frequency, hesitancy, intermittency and a decrease in the size and force of the voided stream. He had experienced no pain in the bones or other constitutional symptoms. The prostate was found to be markedly enlarged, irregular, nodular and fixed, with extension into both seminal vesicles and lateral pelvic walls. All preliminary studies gave negative results, except for increase of the sedimentation rate to 15 mm. per hour. The urinary 17-ketosteroids were 2.2 mg. per day, serum acid phosphatase 2.7 units and serum alkaline phosphatase 4.3 units. Roentgenograms of the bone failed to show metastasis. Perineal biopsy showed an adenocarcinoma of the prostate. A sternal biopsy gave a negative result.

From the twenty-fifth day (fig. 3) he was given 25 mg. of testosterone propionate daily. This was increased to 100 mg. daily on the forty-seventh day and maintained at this dosage until the sixty-seventh day, when it was stopped. Shortly after the use of testosterone was begun, severe diarrhea developed, which disappeared within one week. Otherwise the patient showed no symptomatic changes during his entire course in the hospital. Repeated rectal examinations disclosed a

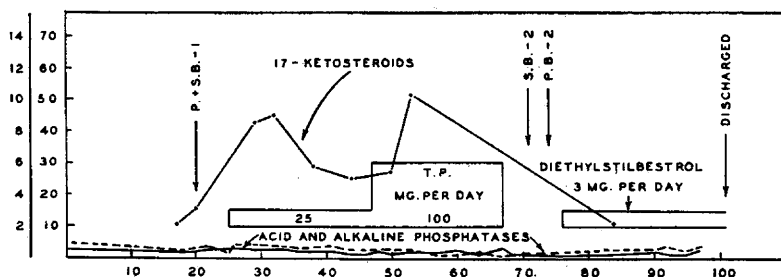


Fig. 3 (case 3).—Ordinates, to 17-ketosteroids in milligrams per day (0 to 26); acid and alkaline serum phosphatase (0 to 130 units). Abscissa, days. P. B.-1 and P. B.-2 represent perineal biopsies; S. B.-1 and S. B.-2 represent sternal biopsies.

definite increase in the size of the prostate to the point where it completely engirdled the rectum.

Urinary steroids rose during administration of testosterone and fell when administration of the drug was stopped. No changes were observed in either acid or alkaline serum phosphatases. No visible bone metastasis developed on serial roentgenograms. A subsequent sternal biopsy showed no evidence of metastatic cancer, but changes were observed in the tissue removed at perineal biopsy which were similar to those observed in case 2.

On the seventy-sixth day because of persistent symptoms of obstruction of the vesical neck, administration of diethylstilbestrol was begun, 1 mg. daily. This was continued throughout the remainder of his stay in the hospital, and on this treatment the urinary symptoms improved.

COMMENT

We have described the clinical and laboratory findings in 3 patients with advanced prostatic cancer who received testosterone propionate in doses varying from 25 to 100 mg. daily for periods up to two months. Two of these 3 patients had extensive secondary involvement of bone, and 1 of these 2 had previously been castrated and had received estrogen.

We were aware that Huggins and Hodges in 1941 had administered androgen in lesser amounts and for shorter periods to 3 patients with metastatic cancer of the prostate who had previously been castrated.

Several points of interest emerge from this study. We were impressed with the general improvement shown by the 2 patients with metastatic prostatic cancer during the period they received testosterone. Pain in the bones was considerably lessened in the patient who complained of this initially and did not develop in either of the other 2.

As evidenced in roentgenograms, metastasis did not develop in the patient initially free from it, nor did remarkable change occur in the 2 patients with metastasis.

Regarding the serum acid phosphatase, it is significant that further increase occurred in the 2 patients with osseous metastasis but not in the one without it. Perhaps occult bony metastasis can be diagnosed by observing the response of the serum acid phosphatase to a short course of androgen injections.

On the basis of these preliminary studies, we believe that further investigation of the role of androgens in prostatic cancer is warranted. It will be recalled that in cases of metastatic cancer of the breast in the female both androgens and estrogens have been used, androgens apparently exerting a more beneficial effect in younger women and estrogens in the older age group. Furthermore, androgens appear to affect osseous metastasis predominantly, whereas estrogens primarily influence the soft tissue metastasis and the primary growth itself.⁷ Perhaps an analogous situation exists with reference to prostatic cancer. It is our feeling that reliable information can be obtained only through careful studies which utilize all available technics. In the last analysis, however, the validity of such studies must depend on the manner in which patients are selected. Only then can the relative efficacy of different forms of therapy be properly evaluated.

7. Adair, F. E., and Hermann, J. B.: Use of Testosterone Propionate in Treatment of Advanced Carcinoma of the Breast, *Ann. Surg.* **123**:1023, 1946.
Nathanson, I. T.: Estrogen Influence on Advanced Carcinoma of the Breast: Preliminary Observations, read at the "Cancer Symposium" of the Thirty-Second Clinical Congress of the American College of Surgeons, December 18, 1946.